
Insertion and Removal of Vaginal Mesh for Pelvic Organ Prolapse

TYLER M. MUFLY, MD and MATTHEW D. BARBER
MD, MHS

*Department of Obstetrics and Gynecology, Center for
Urogynecology and Pelvic Reconstructive Surgery, Obstetrics,
Gynecology and Women's Health Institute,
Cleveland Clinic, Cleveland, Ohio*

Abstract: A variety of surgical meshes are available to correct pelvic organ prolapse. This article discusses benefits and risks of vaginal mesh use. Emphasis is placed on the appropriate surgical technique to improve outcomes and minimize mesh complications. Placement options are reviewed with the discussion of self-tailored mesh, trocar-based mesh kits, and non-trocar mesh kits. This article also reviews the management of mesh complications including the technique for mesh removal.

Key words: pelvic organ prolapse, surgical mesh, mesh kits, mesh erosion

Introduction

Pelvic organ prolapse is one of the most common indications for surgery in women with approximately 200,000 inpatient surgical procedures performed for this indication in the United States annually.¹

Correspondence: Matthew D. Barber, MD, MHS, Section of Urogynecology and Pelvic Reconstructive Surgery, Obstetrics, Gynecology and Women's Health Institute, Cleveland Clinic, Desk A81, Cleveland, OH. E-mail: barberm2@ccf.org

The authors have no potential conflicts of interest.

A woman's risk of requiring surgery for prolapse is approximately 7% by the age of 80 years.¹ Of those who receive surgery, an estimated 13% will require a repeat operation within 5 years and as many as 29% will undergo another surgery for prolapse or a related condition at some point during their life.^{1,2} Given the rates of prolapse recurrence after surgery, many pelvic reconstructive surgeons have incorporated the use of synthetic or biologic graft materials into their repairs in an attempt to improve outcomes. The concept of using mesh or grafts to improve native tissue repairs is not novel. The use of synthetic mesh for inguinal and ventral hernia repair is well supported in the general surgery literature and is currently considered the "gold standard" approach.³ The use of synthetic mesh during sacral colpopexy to suspend the vaginal apex from abdominal or laparoscopic approach is well established and supported by level I evidence.⁴ In the last 5 years, there has been an increase in the use of synthetic and biologic mesh to

augment transvaginal prolapse surgery. This has largely been driven by the recent availability and marketing of commercially available pre-packed mesh delivery systems or “mesh kits.” Despite a paucity of consistent data, the use of new synthetic materials, including mesh kits, is rapidly expanding. In this chapter, we will summarize the potential benefits and risks associated with vaginal mesh use, describe the currently available synthetic and biologic graft materials, review the various surgical approaches for vaginal mesh placement, and provide a step-wise approach for managing postoperative mesh complications.

Benefits and Risks of Vaginal Mesh Use

Current data is sparse, but suggests that the use of mesh or graft to augment vaginal prolapse surgery is associated with both potential benefits and risks. The pelvic surgeon must carefully consider the balance of these benefits and risks when considering the use of mesh for transvaginal prolapse repair. Most data on the outcomes and complications after transvaginal mesh placement has consisted of retrospective or uncontrolled case series. More recently, a few randomized, controlled trials have been published which demonstrate improved anatomic outcomes, but similar subjective outcomes and higher complication rates after mesh placement when compared with traditional vaginal repairs.^{5,6} In 2008, the Society of Gynecologic Surgery (SGS) systematically reviewed the literature and published clinical practice guidelines on vaginal graft use.⁷ In this statement, the authors made the following conclusions based on the literature available at the time of their review:

- Native tissue repair remains appropriate when compared with biologic graft use or absorbable synthetic graft use for all compartments
 - Nonabsorbable synthetic graft use may improve anatomic outcomes of the anterior vaginal wall, but there are trade-offs in regard to additional risks
 - There are no comparative studies to guide any recommendation on the use of nonabsorbable synthetic mesh in the posterior or apical compartments when compared with native tissue repair.
- They noted, however, that no high or even moderate quality evidence existed to guide their recommendations and that in some cases evidence was so limited that no recommendation could be offered. As such, they emphasized that future research was likely to have an important effect on their estimates and may even change them.⁷ Similar to the SGS review, the Cochrane Collaboration completed a systematic review and concluded that the use of mesh or graft inlays at the time of anterior vaginal wall repair may reduce the risk of recurrent cystocele, but that there was insufficient evidence to make recommendations for posterior vaginal wall or apical repair.⁸
- Potential complications related to graft and mesh include erosion, infection, dyspareunia, fistula, and chronic pain.⁹ Rates of these complications vary greatly and have not always been consistently reported. Erosion of mesh varies after vaginal prolapse repair varies widely from 3% to 17% 3 to 12 months after placement with synthetic mesh carrying a greater risk than biologic grafts.^{5,10} Multifilament mesh has a higher rate of erosion and complication than wide pore monofilament mesh. Additional risk factors include concurrent hysterectomy and tobacco use. Although some experienced surgeons have reported erosion rates as low as 2% to 3%, the largest series describing short-term complications in 289 women noted an erosion rate of 10% with transvaginal placement of loosely woven polypropylene mesh.¹¹
- Other complications such as fistula, de novo dyspareunia, and chronic pain

have also been reported but mostly in case reports and small series. In October 2008, the Food and Drug Administration (FDA) issued a public health notification (<http://www.fda.gov/cdrh/safety/102008-surgicalmesh.html>) and made recommendations regarding the serious complications associated with transvaginal placement of surgical mesh for the repair of pelvic organ prolapse and stress urinary incontinence in which they describe receiving 1000 reports of complications over 3 years (Table 1). The most frequent complications noted in the FDA public health notification included erosion through vaginal epithelium, infection, pain, urinary problems, and recurrence of prolapse and/or incontinence. Also noted was vaginal scarring, which in some cases led to a significant decrease in patient quality of life due to discomfort and pain, including dyspareunia.

A recent randomized trial by Hiltunen et al⁵ that compared anterior colporrhaphy with and without polypropylene mesh augmentation provides a good example of both the benefits and risks of vaginal mesh use. In this trial, the cure rate 12 months after surgery (defined as pelvic organ prolapse quantification stage 0 or 1) was significantly higher after the mesh-augmented repair compared with standard anterior colporrhaphy (61.5% vs. 93.3%, $P < 0.001$). However, symptomatic cure (absence of vaginal bulge symptoms)

was noted in 94% and 93%, respectively ($P = 0.90$), the proportion with stage 3 or 4 prolapse was similar 3% versus 0% ($P = 0.11$) and the rate of reoperations for prolapse recurrence was only 1% in each group. Moreover, the women whose surgery was augmented with mesh had a higher rate of new onset stress urinary incontinence (22% vs. 10%, $P < 0.02$) and mesh exposure (17% vs. 0%).⁵ This trial illustrates the balance of risks and benefits that the surgeon and patient must consider before considering the use of vaginal mesh or graft for the treatment of pelvic organ prolapse.

To summarize, the current evidence would support the use of synthetic mesh to augment repairs of anterior vaginal prolapse but at the expense of an increased rate of complications, particularly mesh exposure. More data is needed to determine the role of synthetic vaginal mesh use for posterior vaginal wall and apical prolapse and to determine the role of biologic grafts in vaginal prolapse repairs for all segments.

Indications and Preoperative Preparation

Given the current state of the literature, clinical judgment must be relied upon to determine the indications for using transvaginal mesh use at this time. Surgeons' views differ as to when using mesh for this

TABLE 1. FDA Administration Public Health Notification Recommendations: Serious Complications Associated with Transvaginal Placement of Surgical Mesh in Repair of Pelvic Organ Prolapse and Stress Urinary Incontinence

Obtain specialized training for each mesh placement technique and be aware of its risks
Be vigilant for potential adverse events from the mesh, especially erosion and infection
Watch for complications associated with the tools used in transvaginal placement, especially bowel, bladder, and blood vessel perforations
Inform patients that implantation of surgical mesh is permanent, and that some complications associated with the implanted mesh may require additional surgery that may or may not correct the complication
Inform patients about the potential for serious complications and their effect on quality of life, including pain during sexual intercourse, scarring, and narrowing of the vaginal wall (in pelvic organ prolapse repair)
Provide patients with a written copy of the patient labeling from the surgical mesh manufacturer, if available

indication is justified. Some surgeons feel that transvaginal mesh is indicated for primary repair in any patient who seeks durability and who are willing to accept the known risks of surgery. Others choose to be more cautious and only use mesh in elderly women who are not sexually active. Many surgeons consider a mesh-augmented repair for recurrent prolapse or for patients with a high risk of prolapse recurrence. Well-known risk factors for recurrent prolapse include connective tissue disorders, chronic pulmonary disorders, stage 3-4 prolapse, and a history of smoking. In contrast, some clinicians feel that the risks of transvaginal mesh placement outweigh the benefits and only offer native tissue repair. At the Cleveland Clinic, we generally reserve the use of transvaginal mesh for women who have recurrent isolated anterior vaginal prolapse with a well-supported apex. Another population in which we are using transvaginal mesh is women with stage 3-4 uterovaginal prolapse who desire uterine preservation but not future child-bearing. To date, no studies have compared the impact of these patient selection factors on success of pelvic organ prolapse repair using transvaginal mesh.

There are several situations where mesh use is contraindicated. Many surgeons would not consider the use of mesh in a patient who has had a previous mesh complication. Mesh augmentations should not be used in pregnant women or women who are contemplating future pregnancy as the mesh does not stretch significantly as the patient grows. In patients who have had pelvic radiation, mesh placement is not recommended because of the risk of poor wound healing. Similarly, preexisting local or systemic infection is a contraindication for vaginal mesh placement, particularly nonabsorbable synthetic mesh. Most surgeons would not recommend the use of nonabsorbable synthetic mesh if colorectal surgery is being performed concurrently.

It is also important to consider preoperative patient characteristics when weighing the risks and benefits of transvaginal mesh use for a particular patient. Patients with significant urogenital atrophy who have thin vaginal walls may be at risk for mesh erosion or exposure after mesh placement. Most experts would advocate local estrogen therapy preoperatively provided there are no contraindications to its use. Chronic steroid use, smoking, uncontrolled diabetes mellitus, or other causes of a compromised immune system can impair wound healing and may warrant consideration of these conditions relative contraindications to vaginal mesh placement. Pelvic pain syndromes such as endometriosis, vulvodynia, interstitial cystitis, fibromyalgia, and dyspareunia should be evaluated preoperatively to allow for comprehensive counseling as to the best surgical and nonsurgical form of treatment.

In addition to a history of chronic pain, current and future sexual activity is another factor to consider when choosing a transvaginal mesh procedure. Mesh does not have the same elasticity as the vaginal wall and therefore may alter the functionality of the vagina. A recent study addressed the question of whether transvaginal mesh placement worsens sexual function 1 year postoperatively. Among women with low or no dyspareunia symptoms at baseline, 23% complained of new onset dyspareunia after transvaginal mesh placement. However, in women with higher rates of dyspareunia preoperatively, 45% had improvement postoperatively. Altman et al¹² concluded that overall sexual function worsened after vaginal mesh placement, but the rates and severity of dyspareunia neither improved nor worsened. Some surgeons do not place permanent synthetic mesh in sexually active women because of reported *de novo* dyspareunia and/or altered sexual function.

More research is needed on the ideal candidate for mesh placement. In most cases, the decision to use or not use

mesh is based on the surgeon’s best clinical judgment after carefully weighing the risks and benefits for the individual patient. This must be accompanied by careful preoperative counseling so that the patient is fully aware of the potential benefits and risks and can make an informed decision. A significant emphasis of the FDA notification was proper preoperative counseling before transvaginal mesh placement. This counseling includes informing patients about the following: (1) implantation of surgical mesh is permanent, (2) some complications associated with the implanted mesh may require additional surgery that may or may not correct the complication, and (3) there is the potential for serious complications that may affect quality of life, including pain during sexual intercourse, scarring, and narrowing of the vaginal wall.

Transvaginal Mesh Materials

After deciding to use surgical prostheses, the surgeon will have multiple materials from which to choose. The ideal prosthesis is nonallergenic, noncarcinogenic, not modified by tissue fluid, no immune response, manufactured to shape, sterile, resistant to infection, prevents adhesions, and fails at suprphysiologic tensile strength.¹³ Today’s mesh materials include absorbable and nonabsorbable synthetic mesh and biologic grafts. Currently available absorbable synthetic mesh includes Polyglactin 910 and polyglycolic acid (Fig. 1).

There are several categories of non-absorbable mesh used in pelvic floor reconstruction. Amid et al¹⁴ classified materials based on pore size because of its association with infection risk. Mesh with pores greater than 75µm in size allows the free passage of leukocytes and macrophages which minimizes the risk of infection. Monofilament synthetic meshes that have interstices that are smaller than this may increase the risk of infection. All the products examined in this article use monofilament Amid Type I macroporous structure (>75µm) made from polypropylene which is the current mesh of choice for vaginal prolapse repair. Polypropylene has a low flexural rigidity and is able to remain inert in an infected field. Recent generations of synthetic mesh use a loose weave to make it more accessible to fibroblast migration. This structure is said to prevent encapsulation and scar formation.

To address problems of dyspareunia and vaginal stiffness, many manufacturers have recently attempted to improve the biologic integration and mechanical elasticity of synthetic mesh by incorporating absorbable synthetic materials or biologic materials with polypropylene mesh. One example is the Prolift + M (Ethicon Women’s Health & Urology, Sommersville, NJ), which consists of poliglecaprone-25 knitted with polypropylene mesh. In 3 months, the poliglecaprone-25 is absorbed leaving a lower burden of polypropylene in the vagina

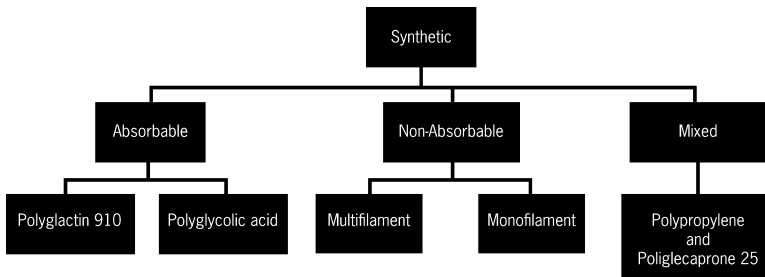


FIGURE 1. Synthetic mesh in surgery.

than the classic Prolift kit.¹⁵ Some mesh products like the Avaulta Anterior Plus (CR Bard, Inc, Covington, GA) have a hydrophilic porcine collagen biologic coating to minimize tissue adhesions. The absorbable coating is said to limit adhesion formation by acting as a mechanical barrier in the first 10 to 14 days after surgery when inflammation peaks. Little or no clinical data exists evaluating whether these newer multimaterial products improve outcomes or decrease complication rates compared with standard loosely woven polypropylene mesh. Currently no products meet all the required characteristics of the ideal pelvic reconstructive surgery prosthesis.

Biologic grafts used in reconstructive surgery can broadly be divided into those derived from human tissue (allografts) and those derived from other species (xenografts) (Fig. 2). Although commonly used to augment anterior and posterior vaginal prolapse repairs, there is no available evidence suggesting the use of these grafts improve outcomes. Both the Cochrane Review and the SGS systematic review concluded that current evidence suggests that augmentation of anterior and posterior vaginal prolapse repair with

biologic graft does not improve anatomic outcomes when compared with native tissue repair.^{7,8} In fact, one trial of rectocele repair noted worse anatomic outcomes with the use of a porcine-derived, acellular collagen matrix graft compared with traditional posterior colporrhaphy.¹⁶ As such, the routine use of biologic grafts in prolapse repair cannot be recommended. If the surgeon determines that graft augmentation is warranted there are, however, certain circumstances where biologic grafts might be considered over permanent synthetic grafts including history of a complication from synthetic mesh or concurrent colorectal resection.

Review of Mesh Placement Options

The 3 general categories of transvaginal mesh placement options for the management of pelvic organ prolapse are: (1) self-tailored mesh, (2) commercially available trocar-guided mesh kits that use a trans-obturator and/or transgluteal approach, and (3) commercially available mesh kits that do not use trocars but rather one of a variety of transvaginal fixation methods (non-trocar kits).

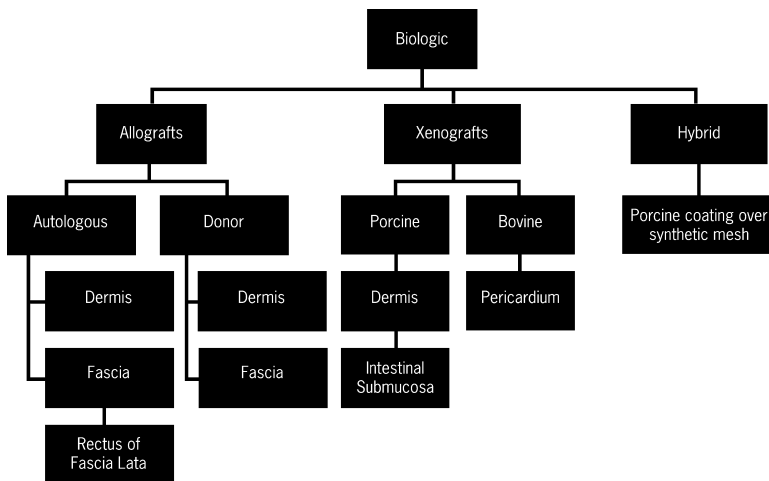


FIGURE 2. Biologic graft implants.

No matter what placement option is used, the general surgical approach to treat anterior vaginal wall prolapse is fixation of mesh to the arcus tendineus fascia pelvis (ATFP) or the iliococcygeus muscle (Table 2). A deep sagittal colpotomy incision is made into the paravesical and pararectal spaces using copious hydrodissection. The mesh is spread laterally toward the ATFP proximally and distally. Similarly, most mesh is fixed to the sacrospinous ligament or the pre-spinous musculature and the ATFP to address posterior prolapse.

Pelvic surgeons began using a self-tailored mesh for mesh augmentation prolapse repair because ligamentous fixation

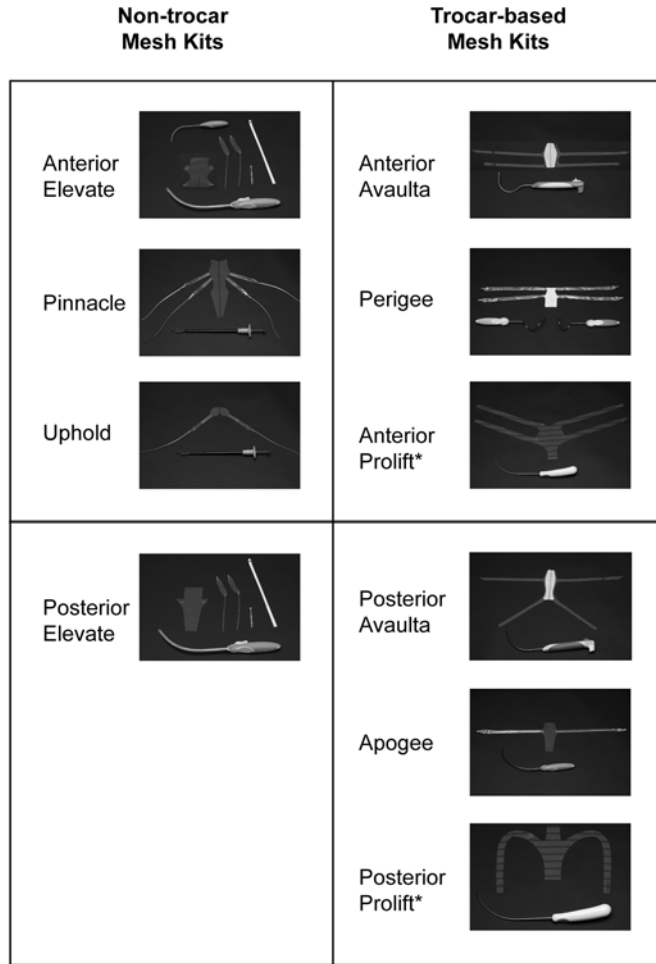
points can vary among patients on account of the 4 basic types of bony pelvis configurations. The trocar-guided kits currently available include Prolift (Ethicon, Somerville, NJ); Apogee and Perigee (American Medical Systems, Minnetonka, MN); and Avaulta (CR Bard, Murray Hill, NJ). Trocar-guided systems use a precut sheet of graft material with narrow lateral appendages for fixation. Non-trocar mesh kits include Elevate (American Medical Systems, Minnetonka, MN) as well as Pinnacle and Uphold (Boston Scientific, Natick, MA) (Fig. 3).

Despite the lack of evidence that any one placement technique is best in managing a patient's symptoms, most experts

TABLE 2. Characteristics of Mesh Kits for Pelvic Organ Prolapse Repair

Name (Company)	Segment	Material	Delivery System	Fixation Point	Cost
Apogee (American Medical Systems)	Posterior apical	Polypropylene ± biologic coating	Transgluteal trocar	Iliococcygeous muscle 1-2 cm distal to ischial spine	\$1595
Perigee (American Medical Systems)	Anterior apical	Polypropylene ± biologic coating	Helical transobturator trocar	ATFP and iliococcygeous muscle 1-2 cm distal to ischial spine	\$1395
Anterior Elevate (American Medical Systems)	Anterior apical	Polypropylene	Trocarless with self-fixating arms	Sacrospinous ligament and obturator internus	\$1895
Posterior Elevate (American Medical Systems)	Posterior apical	Polypropylene	Trocarless with self-fixating arms	Sacrospinous ligament	\$1595
Pinnacle (Boston Scientific)	Anterior apical	Polypropylene	Capio device	ATFP and sacrospinous ligament	\$1899
Uphold (Boston Scientific)	Anterior apical	Polypropylene	Capio device	Sacrospinous ligament	\$1650
Anterior Avaulta (CR Bard)	Anterior apical	Polypropylene ± biologic coating	Transobturator and transgluteal trocars	ATFP and iliococcygeous muscle 1-2 cm distal to ischial spine	\$1695 mesh + \$299 trocar
Posterior Avaulta (CR Bard)	Posterior	Polypropylene ± biologic coating	Transobturator and transgluteal trocars	Iliococcygeous muscle 1-2 cm distal to ischial spine	\$1695 mesh + \$299 trocar
Anterior Prolift (Gynecare)	Anterior	Polypropylene ± poliglecaprone-25	Transobturator trocar with cannula	ATFP	\$1575
Posterior Prolift (Gynecare)	Posterior apical	Polypropylene ± poliglecaprone-25	Transgluteal trocar with cannula	ATFP and sacrospinous ligament	\$1575

ATFP indicates arcus tendineus fascia pelvis.



* Can be provided as a total pelvic floor mesh kit.

FIGURE 3. Comparison of mesh and trocars.

would agree on some basic perioperative tenets:

- The bladder should be drained with a transurethral catheter.
- A well-estrogenized vaginal wall is preferred before surgery [we use intravaginal estrogen cream daily (0.5 to 1.0 g/d) for 2 to 3 wk preoperatively]. A vaginal pessary should be removed 1 to 2 weeks before surgery to limit vaginal epithelium irritation.
- As with all pelvic reconstructive surgery, the procedure should be initiated after antibiotic prophylaxis with a first or second generation cephalosporin 1 hour before surgery (cefuroxime 1.5 g intravenously).
- All techniques should be performed with the patient in the dorsal lithotomy position with the knees flexed to 90 degrees.
- Avoid making inverted “T-shaped” incisions from a concurrent hysterectomy and colporrhaphy.
- Exposure of the correct vesicovaginal and rectovaginal planes are performed with hydrodissection of 20 to 80 mL 0.5% lidocaine with 1:200,000 epinephrine, dilute pitressin (20 units in 60 to 100 mL of saline), or normal saline. The correct space for dissection is found using a “loss of resistance” technique similar to that used by an anesthesiologist placing an epidural.

A wheal or blanching illustrates incorrect intraepithelial placement of the fluid. Hydrodissection in the correct plane will create a fluid bubble in the avascular vesicovaginal and rectovaginal spaces.

- As opposed to an anterior colporrhaphy where the vaginal epithelium and muscularis are split for plication, mesh should be placed underneath the vaginal muscularis. It is vital that the surgeon perform a full-thickness dissection deep into the vesicovaginal and rectovaginal spaces to avoid erosion of the mesh postoperatively. Proper hydrodissection, as described above, facilitates the identification of the proper dissection plane.
- The mesh should be placed loosely. Loosely place the prosthesis because mesh can contract by up to 20% after placement compromising vaginal length and caliber. Allow enough room for Mayo scissors to be easily placed between the mesh and the vagina. In addition, ensuring that the mesh is placed flat and minimal tension will improve fibroblast growth and minimize complications of pain or erosion.
- The vaginal epithelium should not be trimmed. Trimming the vaginal epithelium can lead to discomfort and may also contract. The colpotomy incision is closed using a non-locking continuous absorbable suture.
- Cystoscopy, digital rectal examination and, if necessary, protoscopy should be performed routinely after mesh placement to identify potential visceral injury.

SELF-TAILORED MESH PLACEMENT FOR PROLAPSE REPAIR

Self-tailored mesh can be customized by the surgeon to match the size and shape of each patient's individual pelvic anatomy. Mesh is cut into a trapezoid multiarmed shape for compartment augmentation and fixed to sacrospinous ligaments, obturator fascia, ATRF, and/or the distal bladder neck (Fig. 4).¹⁷ This type of surgery requires a strong set of vaginal surgical skills as it involves dissections similar to sacrospinous ligament fixation, iliococcygeus suspension, uterosacral suspen-

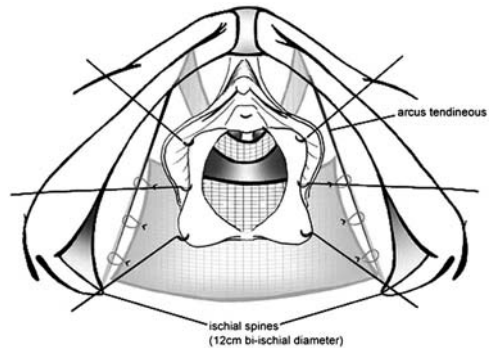


FIGURE 4. Use of a surgeon tailored mesh into a trapezoid shape and attached to the arcus tendineus fascia pelvis. From *Am J Obstet Gynecol.* 2006;195:1832–1836.

sion, and infracoccygeal sacropexy. No studies have compared standard repair techniques using self-tailored mesh with other mesh placement techniques.

TROCAR-BASED MESH KITS

Trocar-guided devices can be used to suspend mesh by passing needles through the transobturator and ischioanal fossa. Although a variety of different kits are available, the technique is generally similar. For kits designed to augment the anterior vaginal segment, a weighted speculum, self-retaining retractor, or Deaver retractors are placed in the vagina. Allis clamps are positioned at the urethrovesical junction for traction and 1 cm proximal to the vaginal apex. The bladder can be palpated between the 2 Allis clamps. As opposed to an anterior colporrhaphy in which the vaginal epithelium and muscularis are split for plication, the mesh is placed underneath the muscularis to maintain a vascularized epithelium. To enter this potential space, the surgeon injects a dilute vasopressin solution of 0.5% lidocaine with 1:200,000 epinephrine underneath the vaginal muscularis to facilitate dissection and minimize blood loss. Irrigation may help during the dissection as the defect is a glistening white line. A sagittal colpotomy

incision is made between the Allis clamps long enough to admit 2 fingers comfortably. Next, countertraction along the entire incision line is achieved with either serial Allis clamps or a self-retaining retractor. The vaginal epithelium and muscularis are dissected away from the bladder defect. Sharp and blunt dissection of the bladder is then performed while keeping the muscularis and epithelium on the vaginal flaps. As this full-thickness dissection plane is advanced, superiorly loose areolar tissue is encountered.

The posterior incision is 4 to 5 cm long in the posterior vaginal epithelium 1.5 cm below the vaginal apex. Again, the incision should be deep where the moving tips of the Metzenbaum scissors are not visible as the surgeon removes the muscularis from the rectum side of the dissection. The posterior dissection of the ischiorectal space extends to the level of the ischial spines and the sacrospinous ligament with a combination of sharp and blunt dissection. To perform this posterolateral dissection, we use Briesky-Navratil retractors and long instruments. At the time this step is performed, the mesh is prepared to be placed into the dissected paravaginal and/or pararectal space.

After the mesh is prepared by slightly trimming the precut shape, the prosthesis is implanted. The most common mesh revision is dividing the mesh into anterior and posterior pieces. The mesh should be altered this way if the uterus will be preserved or to maximize apex elasticity. If less than 1 cm of space remains between the anterior and posterior mesh pieces, then enterocele may be prevented. The lateral edges of the mesh may be scalloped as needed in women with narrow pelvises. Cutaneous incisions that are 4 to 7 mm in length are made over the obturator foramen and gluteus to pass trocars. When placing multiple mesh arms through the transobturator space, the superior and inferior puncture sites should be at least 3 cm apart so the mesh can lay flat. Two

fingers placed into the vagina can retract the colon, elevate the bladder, and minimize deviation of the trocar tip with direct palpation. For anterior compartment mesh, the surgeon immediately identifies the incoming trocar passing through the ATFP. The Perigee system uses a proprietary helical trocar which pierces the iliococcygeus muscle rather than the sacrospinous ligament at the level of the ischial spine akin to the IVS Tunneler (Tyco Healthcare, US Surgical, Norwalk, CT). Other transobturator mesh kits such as the Anterior Prolift use a slightly C-shaped curved trocar for passes. Through the posterior dissection, support can also be re-established. The posterior Prolift and Apogee systems tunnel through the ischiorectal fossa to the midportion of the sacrospinous ligament. The prosthesis is loosely placed in a "tension-free" manner because mesh can contract by up to 20% after placement, compromising vaginal length and caliber. A finger should be kept inside the vagina whenever tensioning the graft. This provides countertraction and splints the tissue at the points of fixation. A rectovaginal examination gently pushes cephalad to confirm the absence of tension on the rectum and anterior or posterior trocar-guided mesh appendages. Stay sutures can be used to help the mesh lay flat against the vagina. If the surgeon conserves the uterus, then permanent sutures can be placed into the cervical stroma to stabilize the mesh and prevent enterocele. A cystoscopic and rectal examination before, during, and after each portion of the surgery can be helpful. Once adequate hemostasis is obtained, the vaginal epithelium is closed with a continuous non-locking stitch of delayed absorbable suture. Placing a lubricated vaginal pack may minimize bleeding and keep the mesh flat during healing. After desired tensioning, all ends of the mesh arms should be trimmed below the surface of the skin, the cannulae exteriorized if used, and the

incisions closed. Concurrent procedures, such as a pubovaginal sling, should be carried out through a separate vaginal incision at this time.

NON-TROCAR MESH KITS

Unlike trocar-guided kits, which require a level of comfort with the transobturator space, the non-trocar kits use a standard vaginal sharp dissection approach to the ligaments of the pelvis. Possibly as a result of the general adversity to blind procedures, many surgeons have embraced the total vaginal approach. With completely transvaginal kits, the mesh appendage placement can be carried out under direct visualization.

The technique for the non-trocar kits begins similarly to the technique for trocar-guided kit placement. After the vesicovaginal and/or rectovaginal space(s) are dissected, pertinent fixation points are identified. The sacrospinous ligament mesh arms serve to elevate the prolapsed vagina above the pelvic floor and secure it in a posterior midline axis. The surgeon can identify the ischial spine if he or she displaces the rectum contralaterally. The operator's index and middle fingers are placed at the medial aspect of the patient's ischial spine. Once identified, any fibrous tissue from the sacrospinous ligament point of insertion is cleaned off using a finger sweep medially. The surgeon palpates the location of interest, then identifies the sacrospinous ligament one fingerbreadth medial to the ischial spine. The ligament is penetrated using the surgeon's device of choice. The Pinnacle and Uphold kits use the Capiro transvaginal suture capturing device (Boston Scientific, Natick, MA) to suture the mesh arms to the sacrospinous ligament, and ATRP. Alternatively, the Elevate system (American Medical Systems, Minnetonka, MN) uses self-fixating appendage tips delivered by vaginal trocars to the same site (Fig. 5). The ATRP mesh arms ensure lateral spread. An index finger placed into the

Fixation devices for non-trocar mesh kits

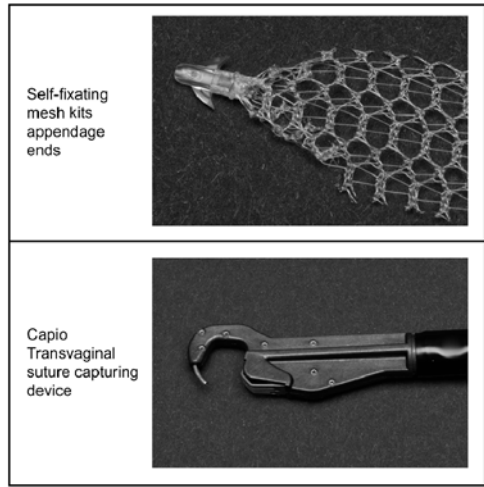


FIGURE 5. Fixation devices for non-trocar mesh kits.

vagina palpates the anterior tendineous fasciae pelvis from the ischial spine to the posterior pubis. The mesh can be passed through the upper third of the ATRP using the same fixation methods. With the Uphold device, there are no ATRP arms to implant. The mesh arms are slowly and individually adjusted to a loose tension, then the mesh is sutured flat. The vagina is minimally trimmed of any areas where Allis clamps may have caused ischemia. When the vaginal epithelium is removed during any procedure, excessive vaginal wall trimming should be avoided because the redundancy of vaginal tissue over the mesh will be reduced as the epithelium scars. The colpotomy is closed and the vagina packed as described above.

Management of Mesh Complications

Mesh or graft erosion, one of the most common postoperative complications, is unique to graft placement. Treatment options consist of observation, treatment with estrogen cream, office excision,

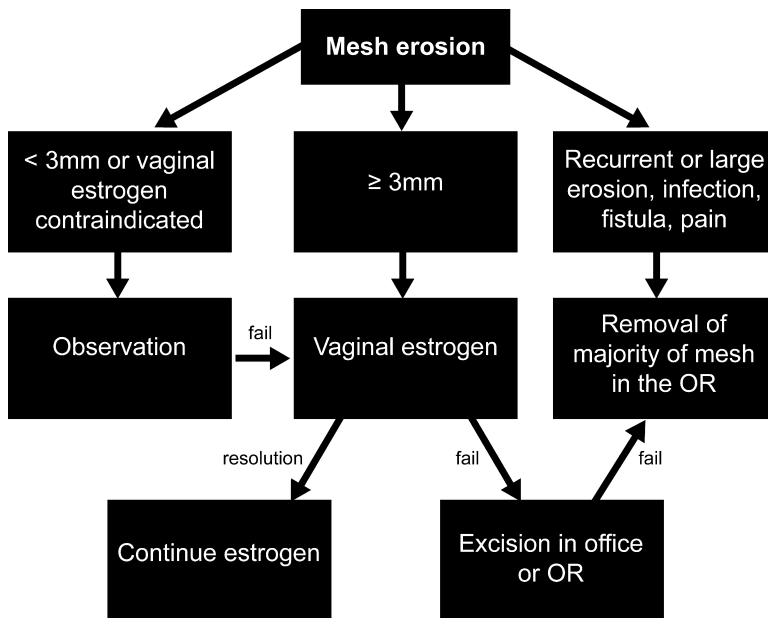


FIGURE 6. Mesh erosion treatment algorithm. OR indicates operating room.

excision in the operating room, and removal of the maximum amount of mesh or graft (Fig. 6). If the patient is asymptomatic, not sexually active, and the erosion is very small (< 3 mm) or if the use of vaginal estrogen is contraindicated, we will consider observation. The patient will be observed at 3 and 6 months and then followed every 6 to 12 months. Although the erosion will often not heal spontaneously, it rarely progresses. For most patients, however, we advocate the use of vaginal estrogen. Admittedly, there is little evidence to suggest an improved rate of healing with vaginal estrogen over observation alone. However, given the known effects of vaginal estrogen on the vaginal epithelium and blood supply, it seems a reasonable conservative option for managing small mesh erosions or exposures. Although many different treatment regimens are available, we will typically use 1 g of vaginal estrogen nightly for 2 weeks and then 3 times weekly thereafter. The systemic absorption is minimal, especially after the first

2 weeks as the epithelium becomes better estrogenized.¹⁸ The patient will return for examination 6 to 8 weeks after treatment is instituted. We continue this regimen if improvement is noted. Some providers use intravaginal metronidazole gel or other intravaginal antibiotic ointments for managing small mesh erosions, however, no data are available on the efficacy of this approach.

If the erosion persists after estrogen use or if the use of vaginal estrogen is contraindicated, we will proceed to mesh excision. When the erosion is less than 5 mm, excision can often be accomplished in the office. The area will be injected with local anesthetic and a clamp (Allis, tonsil) will be used to grasp the mesh or graft. The exposed mesh or graft will be excised sharply. The edges of vaginal epithelium will be trimmed and reapproximated using absorbable suture. If the patient cannot tolerate this procedure in the office, it can easily be accomplished in the operating room. When the mesh exposure is larger than 5 mm, we prefer to perform

this procedure in the operating room, as more tissue has to be mobilized and reapproximated. In these cases, the mesh is excised as described above. The edges of the vaginal epithelium are mobilized, creating a 5 to 10 mm circumferential flap. Then, the vaginal epithelium is reapproximated. Care should be taken to avoid putting tension on the repair or narrowing the vagina. Postoperatively, we treat patient with vaginal estrogen until the area is well-healed.

In cases where mesh excision has failed, when the exposure is greater than 1 to 2 cm, or when infection, fistula, or chronic pain is present, we advocate removal of the majority of the mesh. Although this procedure can be technically difficult, our experience suggests that it can be performed safely with few complications and high relief of symptoms, although some symptoms can persist.¹⁹ If the mesh was originally placed from a completely transvaginal approach, then it may be possible to remove the mesh in its entirety. If trocars were used to place the mesh, as is the case with many commercially available mesh kits, it is often not possible or prudent to remove the arms of the mesh because they pass through the ischioanal fossa and/or obturator space. In these cases, we advocate removal of as much of the mesh as possible through a vaginal approach while leaving the mesh arms in place. Our technique for transvaginal mesh removal is as follows:

1. At the initial clinic visit, the operative notes are requested and reviewed. This allows preoperative planning and provides expectations that guide initial surgical dissections.
2. An examination under anesthesia is performed and the problematic areas of mesh are identified. The mesh is usually easy to palpate vaginally and rectally. Initial cystoscopy, rectal examination, and/or proctoscopy are used to identify the presence of mesh in the bladder or rectum on a case-by-case basis. A Lone Star retractor (CooperSurgical, Trumbull, CT) is used to aid visualization and exposure.
3. The vaginal epithelium covering the mesh is injected with a dilute vasoconstricting agent for hydrodissection and hemostasis. The vaginal epithelium is then opened with a scalpel, and the flaps of the vaginal epithelium are developed with sharp dissection, using a similar technique seen in the initial steps of mesh placement. Care is taken to develop a vaginal epithelium flap as thick as possible to prevent button holes and tearing, which can require removal of a large portion of the epithelium, thereby placing the patient at risk for vaginal narrowing. This dissection is performed as far laterally as possible to achieve adequate visualization.
4. When removing polypropylene mesh, the surgeon will find it often interlaced with fibrotic scar tissue, whereas biologic graft tends to be encapsulated. For mesh, once the layer containing the mesh and the fibrotic overlay is identified, the surgeon mobilizes this layer away from the bladder or rectum, starting either in the midline or laterally, wherever access is easier. Laterally, an instrument such as a right angle clamp, Kelly clamp, or tonsil clamp is used to undermine beneath the mesh tissue layer to provide a starting point. In cases where there is no access laterally, the mesh is incised in the midline using a scalpel, taking care to avoid the underlying bladder or rectum.
5. Once an edge is identified, it is then grasped with Allis clamps to provide traction. The bladder or rectum is then dissected off the mesh, using sharp dissection with scissors and gentle blunt dissection to peel the underlying tissue or vaginal skin from the mesh (Fig. 7). Hydrodissection, firm traction of the mesh flap away from the bladder or rectum, and pointing the tips of the Metzenbaum scissors toward the mesh and away from the bladder or rectum are used to avoid visceral injury. This traction is also valuable in visualizing the lateral mesh arms (Fig. 8).
6. Once the mesh arms are visualized, tension is used to expose the maximum amount of mesh. The mesh arms are transected at the most lateral aspect possible.

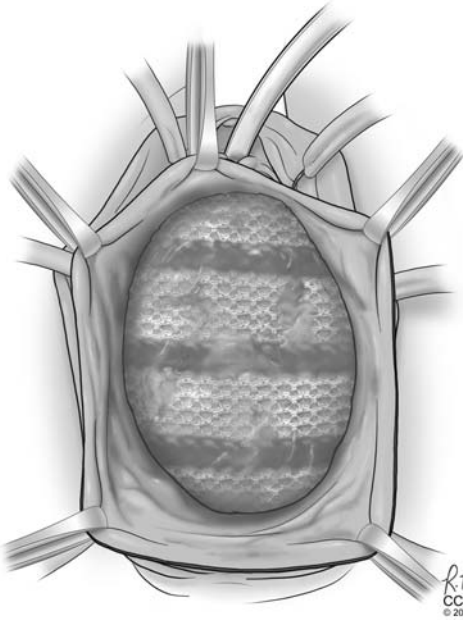


FIGURE 7. The vaginal epithelium was opened with a scalpel and flaps of vaginal epithelium were developed with sharp dissection, using a similar technique seen in the initial steps of colporrhaphy.

Neovascularization of the mesh arms is frequently noted and suture ligation of the arms and surrounding tissue is often necessary to control bleeding (Fig. 9). Controlling bleeding is especially important when dissecting the posterior mesh arms as it requires entry into the ischiorectal fossa where bleeding is often encountered.

7. For the excision of posterior mesh, a finger placed in the rectum during dissection is used to delineate the superior, inferior, and lateral borders of the mesh and further helps to avoid proctotomy.
8. As discussed above, it is often not possible to remove all of the mesh, including the lateral portions of the mesh arms traveling through the obturator foramen and ischiorectal fossa. Once the excision is complete and hemostasis is achieved, the vaginal epithelium is then reapproximated. If recurrent prolapse is present, concomitant procedures to correct pelvic organ prolapse using native tissue can be performed when necessary. We do not advocate placing

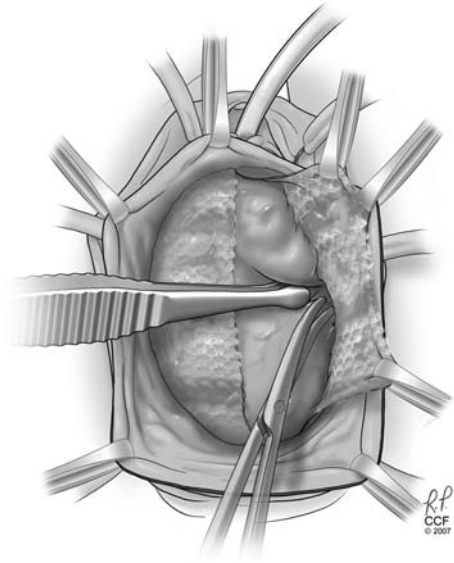


FIGURE 8. The bladder or rectum was dissected off the mesh, using sharp dissection with scissors and gentle blunt dissection with a peanut, finger, or sponge to peel the underlying tissue or vaginal skin from the mesh.

mesh or graft for the treatment of recurrent prolapse at the time of mesh removal.

9. Upon completion, cystoscopy and rectal examination and/or proctoscopy are performed

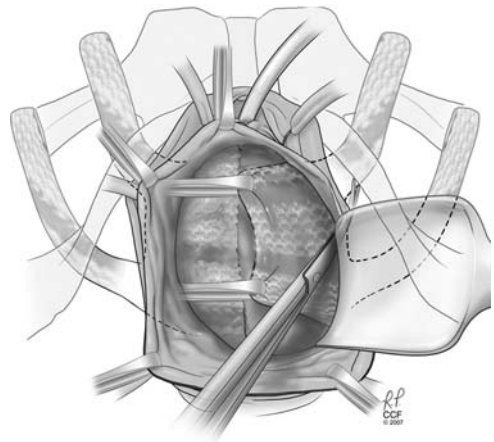


FIGURE 9. Once a mesh edge was identified, it was grasped with Allis clamps to provide traction. This traction was also valuable in visualizing the lateral mesh arms.

to rule out visceral injury. The vagina is packed overnight to assist with hemostasis.

Conclusions

In conclusion, the use of synthetic mesh for transvaginal repair of pelvic organ prolapse results in improved anatomic outcomes for the anterior vaginal wall but with a higher rate of complications when compared with traditional native tissue repairs. There is currently insufficient data to determine the role of transvaginal mesh for apical or posterior vaginal wall prolapse. Moreover, there are no long-term data for pelvic floor repairs using mesh and therefore informed consent for transvaginal mesh placement should be a thorough process. There remains little data regarding the ideal prosthesis delivery that minimizes morbidity while maximizing anatomic and subjective outcomes. Thus, treatment should be individualized, based on provider experience and patient preference, depending on their tolerance for risk. All patients considering transvaginal mesh should be offered a copy of the FDA public health notification, before providing consent. In addition, the patient should be provided a written copy of the labeling from the surgical mesh manufacturer, if available. Document that an adequate trial of medical or nonsurgical management has been offered and attempted or refused (informed refusal) before any operative procedure. Unknown durability and lack of long-term data are the unique risks of mesh and should be discussed. Physicians who have a strong understanding of the consent process and the variety of various mesh options will be best prepared to illustrate the risks and benefits of transvaginal mesh.

References

1. Olsen AL, Smith VJ, Bergstrom JO, et al. Epidemiology of surgically managed pelvic organ prolapse and urinary incontinence. *Obstet Gynecol.* 1997;89:501–506.
2. Clark AL, Gregory T, Smith VJ, et al. Epidemiologic evaluation of reoperation for surgically treated pelvic organ prolapse and urinary incontinence. *Am J Obstet Gynecol.* 2003;189:1261–1267.
3. Scott N, Go Peter MNYH, Graham P, et al. *Open mesh versus non-mesh for groin hernia repair.* Chichester, UK: John Wiley & Sons, Ltd; 2001.
4. Maher C, Baessler K, Glazener CM, et al. Surgical management of pelvic organ prolapse in women: a short version Cochrane review. *Neurourol Urodyn.* 2008;27:3–12.
5. Hiltunen R, Nieminen K, Takala T, et al. Low-weight polypropylene mesh for anterior vaginal wall prolapse: a randomized controlled trial. *Obstet Gynecol.* 2007;110(2 Pt 2):455–462.
6. Nguyen JN, Burchette RJ. Outcome after anterior vaginal prolapse repair: a randomized controlled trial. *Obstet Gynecol.* 2008;111:891–898.
7. Murphy M. Society of Gynecologic Surgeons Systematic Review. Clinical practice guidelines on vaginal graft use from the society of gynecologic surgeons. *Obstet Gynecol.* 2008;112:1123–1130.
8. Maher C, Baessler K, Glazener CM, et al. Surgical management of pelvic organ prolapse in women. *Cochrane Database Syst Rev.* 2007;3:CD004014.
9. Diwadkar GB, Barber MD, Feiner B, et al. Complication and reoperation rates after apical vaginal prolapse surgical repair: a systematic review. *Obstet Gynecol.* 2009;113(2 Pt 1):367–373.
10. Debodinance P, Berrocal J, Clave H, et al. Changing attitudes on the surgical treatment of urogenital prolapse: birth of the tension-free vaginal mesh. *J Gynecol Obstet Biol Reprod.* 2004;33:577–588.
11. Abdel-Fattah M, Ramsay I, West of Scotland Study Group. Retrospective multicentre study of the new minimally invasive mesh repair devices for pelvic organ prolapse. *BJOG.* 2008;115:22–30.
12. Altman D, Elmer C, Kiilholma P, et al. Sexual dysfunction after trocar-guided transvaginal mesh repair of pelvic organ

- prolapse. *Obstet Gynecol.* 2009;113:127–133.
13. Cosson M, Debodinance P, Boukerrou M, et al. Mechanical properties of synthetic implants used in the repair of prolapse and urinary incontinence in women: which is the ideal material? *Int Urogynecol J Pelvic Floor Dysfunct.* 2003;14:169–178; discussion 178.
 14. Amid PK, Shulman AG, Lichtenstein IL, et al. Biomaterials for abdominal wall hernia surgery and principles of their applications. *Langenbecks Arch Chir.* 1994;379:168–171.
 15. Cobb WS, Kercher KW, Heniford BT, et al. The argument for lightweight polypropylene mesh in hernia repair. *Surg Innov.* 2005;12:63–69.
 16. Paraiso MF, Barber MD, Muir TW, et al. Rectocele repair: a randomized trial of three surgical techniques including graft augmentation. *Am J Obstet Gynecol.* 2006;195:1762–1771.
 17. Simsiman AJ, Lubner KM, Menefee SA. Vaginal paravaginal repair with porcine dermal reinforcement: correction of advanced anterior vaginal prolapse. *Am J Obstet Gynecol.* 2006;195:1832–1836.
 18. Pschera H, Hjerpe A, Carlstrom K. Influence of the maturity of the vaginal epithelium upon the absorption of vaginally administered estradiol-17 beta and progesterone in postmenopausal women. *Gynecol Obstet Invest.* 1989;27:204–207.
 19. Ridgeway B, Walters MD, Paraiso MFR, et al. Early experience with mesh excision for adverse outcomes after transvaginal mesh placement using prolapse kits. *Am J Obstet Gynecol.* 2008;199:703.e1–703.e7.